

# ***Contents***

<i>Foreword by Kathryn M. Larsen, MD</i>	<i>ix</i>
<i>Preface</i>	<i>xi</i>
<i>Contributors</i>	<i>xiv</i>
<b>Part I: Diseases of the Ear, Dizziness, and Facial Paralysis</b>	<b>1</b>
1. History and Examination of the Ear <i>Ali Sepehr, Vanessa S. Rothholtz, and Hamid R. Djalilian</i>	3
2. Ear Pain <i>Hamid R. Djalilian and Sanaz Hamidi</i>	21
3. Ear Drainage <i>Alice D. Lee and Hamid R. Djalilian</i>	57
4. Hearing Loss <i>Vanessa S. Rothholtz and Hamid R. Djalilian</i>	75
5. Tinnitus <i>Hamid R. Djalilian, Vanessa S. Rothholtz, and Sanaz Hamidi</i>	95
6. Ear Plugging <i>Ali Sepehr and Hamid R. Djalilian</i>	105
7. Trauma to the Ear <i>James M. Ridgway and Hamid R. Djalilian</i>	119

8. Facial Nerve Paralysis	137
<i>Hamid R. Djalilian, Sanaz Hamidi, and Amir Deylamipour</i>	
9. Dizziness and Vertigo	153
<i>Hamid R. Djalilian</i>	
<b>Part II: Diseases of the Nose and Sinuses</b>	<b>177</b>
10. History and Examination of the Nose	179
<i>Edward C. Wu, Vanessa S. Rothholtz, and Hamid R. Djalilian</i>	
11. Nasal Obstruction	189
<i>Paul Schalch and Hamid R. Djalilian</i>	
12. Epistaxis	215
<i>Rohit Garg and Hamid R. Djalilian</i>	
13. Nasal Discharge	225
<i>Paul Schalch, Quoc A. Nguyen, and Hamid R. Djalilian</i>	
14. Other Nasal and Sinus Conditions	247
<i>Hamid R. Djalilian</i>	
15. Trauma to the Nose and Face	261
<i>Paul K. Holden, Hamid R. Djalilian, and Brian J. F. Wong</i>	
<b>Part III: Diseases of the Mouth, Throat, and Neck</b>	<b>275</b>
16. The History and Examination of the Mouth, Throat, and Neck	277
<i>Edward C. Wu, Vanessa S. Rothholtz, and Hamid R. Djalilian</i>	
17. Lesions of the Oral Cavity	295
<i>Aaron G. Benson, Ryan Leonard, and Hamid R. Djalilian</i>	

---

18. Sore Throat	325
<i>Mehdi Sina-Khadiv, Paul Schalch, Victor Passy, and Hamid R. Djalilian</i>	
19. Hoarseness	349
<i>Esther L. Fine and Roger L. Crumley</i>	
20. Swallowing Problems	357
<i>Esther L. Fine and Hamid R. Djalilian</i>	
21. Airway Obstruction	385
<i>Gurpreet S. Ahuja and Hamid R. Djalilian</i>	
22. Chronic Cough	417
<i>Roberto L. Barretto and Hamid R. Djalilian</i>	
23. Disorders of the Salivary Glands, Thyroid, and Parathyroid	437
<i>William B. Armstrong</i>	
24. Pediatric and Adult Head and Neck Masses	455
<i>Hau Sin Wong and Jason H. Kim</i>	
25. Neck Pain	481
<i>Hamid R. Djalilian</i>	
26. Trauma to the Neck	493
<i>John F McGuire and Hamid R. Djalilian</i>	
27. Common Otolaryngology Procedures	501
<i>Hamid R. Djalilian, Gurpreet S. Ahuja, Roberto L. Barretto, Hau Sin Wong, and David M. Stone</i>	
28. Danger Signs in Otolaryngology	517
<i>Hamid R. Djalilian</i>	
<i>Index</i>	<i>523</i>

# ***Preface***

This book was written by the faculty at the University of California, Irvine as a guide for the primary care and emergency medicine physicians, residents, and medical students to diagnose and treat conditions affecting the ear, nose, throat, and the head and neck. Contrary to standard texts that discuss diseases one at a time, this text was organized in a symptom-based fashion. This allows the clinician to look at a symptom and, based on the algorithm and the description of the disease, come to a diagnosis. For each problem, we tried to create a guide for diagnosis, what tests to order, how to treat, and when to refer. Two chapters at the end outline the most common danger signs in the head and neck of which the primary care physician should be aware and common procedures in otolaryngology-head and neck surgery. We hope that this book will allow the primary care physician to come to a diagnosis for a complaint in the head and neck in less than 10 minutes.

Sixty years ago, the field of otolaryngology-head and neck surgery was still combined with ophthalmology. Now each field has seven subspecialties. The subspecialization in the field of otolaryngology-head and neck surgery has allowed for better patient care in some areas of the field. Although most problems in the head and neck can be cared for by the general otolaryngologist, some patients will need subspecialty

care. The current subspecialties in otolaryngology include:

- **Otology, Neurotology, and Skull Base Surgery:** This specialty treats the diseases of the temporal bone. These include, ear disease, hearing problems, vertigo and balance issues, facial nerve disorders, and posterior and lateral skull base tumors (eg, acoustic neuromas, etc), and stereotactic radiation (radiosurgery/GammaKnife/CyberKnife) for skull base tumors.
- **Head and Neck Surgery:** This subspecialty cares for the patients with benign and malignant tumors of the head and neck, including upper aerodigestive tumors, salivary gland, thyroid, and parathyroid tumors.
- **Rhinology, Nasal Allergy, and Endoscopic Sinus and Anterior Skull Base Surgery:** This subspecialty treats diseases of the nose and sinuses as well as tumors of the anterior skull base, including pituitary tumors, and so forth. These clinicians also diagnose and treat allergies using immunotherapy.
- **Facial Plastic and Reconstructive Surgery:** Specialists in this field are aesthetic and reconstructive specialists of the head and neck.
- **Laryngology:** This subspecialty treats diseases of the larynx including voice and swallowing disorders.
- **Microvascular Reconstructive Surgery:** These surgeons work in conjunction with head and neck surgeons for reconstruction of complex defects of the head and neck using free flaps. These flaps are brought to the head and neck from other areas of the body and their

vasculature is anastomosed to the head and neck vessels allowing for more functional outcomes after cancer surgery.

- **Pediatric Otolaryngology:** This field is dedicated to the treatment of pediatric patients, especially treatment of the pediatric airway problems.

This book would not be possible without the inspiration from my father, Dr. Mohsen Djalilian, who taught me the basics of otolaryngology and how to be a great physician and teacher, my brother, Dr. Ali Djalilian, who always pushed me to be the best I can be, my mentor, the late Dr. George L. Adams, chairman of Otolaryngology-Head and Neck Surgery at the University of Minnesota, and all the faculty at the University of Minnesota, who were my guiding light in my residency training and beyond, and Dr. Victor Passy at the University of California, Irvine who encouraged me to undertake this project.

Hamid R. Djalilian, MD

## CHAPTER 2

# *Ear Pain*

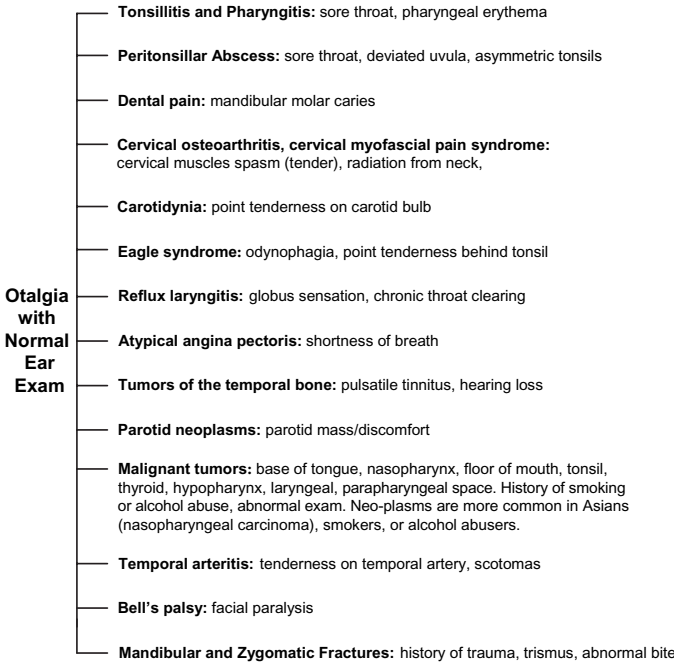
HAMID R. DJALILIAN  
SANAZ HAMIDI

### GENERAL APPROACH TO EAR PAIN

It is not uncommon for a physician to not find any pathology on ear exam of patients with otalgia (Fig 2-1). This is usually due to the complex anatomy and innervation of the ear. Cranial nerves V, VII, IX, X, and the cervical plexus all have branches in the ear that cause referred pain from any pathology in their pathways. It is not unusual that pathology in the teeth, larynx, tonsils, thyroid, parotid, or even GERD can cause ear pain in the patient.

Patients who present with ear pain should be asked about location of pain, what makes the pain better or worse (eg, chewing, swallowing), radiation of pain, and associated symptoms such as sore throat or hearing loss.

Physical examination usually starts with the ear looking for an intact tympanic membrane and a normal external canal. If ear examination is completely normal, then the physician must proceed with examining



**Fig 2–1.** The most common causes of ear pain with a normal ear exam.

the oral cavity, pharynx, neck, parotid, and the facial nerve. On oral cavity/pharynx exam, each tonsil and base of tongue must be palpated for tumors. Also, dental abnormalities (eg, dental caries, evidence of grinding of teeth) must be looked for and a tongue depressor must be used to percuss the mandibular teeth. The temporomandibular joint (TMJ), which is located in front of the ear, should be palpated and the patient is asked to open and close the mouth and elicit tenderness while the physician feels and listens for clicking, and tries to recognize movement of the condyle of the mandible out of the joint (anteriorly or laterally).



## **When to Refer**

Persistent ear pain (beyond 3 weeks) despite conservative therapy or inability to examine the nasopharynx or larynx mandates referral to an otolaryngologist for nasal endoscopy and laryngoscopy. Pain that wakes patient at night despite therapy requires referral as well. Post-trauma patients especially those with abnormal bite after trauma (could indicate mandible fracture), patients with a long history of smoking or heavy alcohol use, or patients with neck mass must also be referred to an otolaryngologist. TMJ problems are referred to a dentist or oral surgeon.

## **OTALGIA WITH A NORMAL EAR EXAM**

## **TEMPOROMANDIBULAR JOINT DISORDERS**

Developmental and congenital anomalies, traumatic injuries, dislocations, ankylosis, arthritis, and neoplasm of temporomandibular joint all can cause referral of pain to the ear and otalgia.

## **Symptoms and Signs**

Trauma to the temporomandibular joint causes difficulty and asymmetry in opening the mouth, periauricular pain, and tenderness over the mandibular condyle. Dislocation of the mandible causes the mouth to remain open. Myofascial pain dysfunction (MPD) syndrome is a disorder that presents with dull pain or acute pain

with jaw movement and limitation of mouth opening. The patient will have radiation of the pain on all parts of the face, ear, and neck where the fascial planes are contiguous. The MPD patients will have tenderness upon palpation of all the facial muscles and the sternocleidomastoid muscle.

### **Diagnosis and What Tests to Order**

The diagnosis of TMJ disorders is based on the tenderness or clicking of the TMJ on movement. A panoramic x-ray of the TMJ can be obtained to look for erosion or arthritis of the TMJ. An oral surgeon may obtain an MRI of the TMJ for a better view of the joint. The diagnosis of MPD is dependent on the tenderness of all facial muscles and their contiguous fascial planes (eg, sternocleidomastoid).

### **Treatment and When to Refer**

Arthritis of the TMJ is treated with heat application on the muscles of mastication (temporalis and masseter) and nonsteroidal anti-inflammatory drugs (NSAIDs) (eg, ibuprofen 600 mg po TID  $\times$  7–14 days). Muscle relaxants (eg, cyclobenzaprine 10 mg TID  $\times$  7–14 days) will also help in symptom relief. The patient must be counseled about home therapy and avoidance of clenching and grinding of the teeth, and a soft diet. Acute dislocation of TMJ should be referred to an oral surgeon or emergency department with access to an oral surgeon. MPD syndrome is treated in the same way as TMJ disorder. If symptoms persist despite all described measures, a referral to a dentist or oral surgeon for a bite appliance is recommended.

## **TONSILLITIS, PHARYNGITIS, OR ANY IRRITATION IN PHARYNX**

Tonsillitis, Pharyngitis, or any irritation in the pharynx can cause ear pain by irritating cranial nerve IX (see Chapter 18).

## **CANCERS OF THE SKULL BASE, PHARYNX, OR LARYNX**

Any cancer in the skull base, pharynx, or larynx can cause ear pain due to the irritation of cranial nerve V, IX, or X. If otalgia continues beyond 2 months despite maximal medical therapy for other presumed causes, a referral to an otolaryngologist is warranted for examination and possible CT of the skull base with contrast.

## **FACIAL PARALYSIS**

Paralysis can cause ear pain by irritation of cranial nerve VII and its branch to the ear canal.

## **CAROTIDYNIA**

These patients most commonly present with pain on the side of the face, neck, and the ear. See Chapter 25 on Neck Pain for carotidynia.

## EAGLE SYNDROME

This syndrome usually presents with a chronic sore throat, but otalgia is also common in these patients. See Chapter 20 on Swallowing Problems.

## LARYNGOPHARYNGEAL REFLUX

See Chapter 18.

## OTALGIA WITH AN ABNORMAL EAR EXAM

The ear is a highly sensitive organ that derives its sensory input from the cervical spine as well as contributing branches from cranial nerves V, VII, IX, and X. This pattern of innervation results in the symptom of otalgia occurring when pathology affects other areas of distribution of the affected nerves. Although ear pain in adults is most commonly referred, many diseases of the ear can cause otalgia. The key to the diagnosis is a thorough, yet directed, history and a physical examination of the ear as well as the temporomandibular joint, the pharynx, and the base of tongue. If the etiology of the otalgia is not discovered with the directed examination, a referral to an otolaryngologist for nasopharyngoscopy and laryngoscopy is required to rule out pathology in those areas. Otalgia with a normal ear examination is discussed in more detail in the previous section. This section is organized starting with abnormalities of the auricle, then proceeding to those of the external auditory canal, and finally the

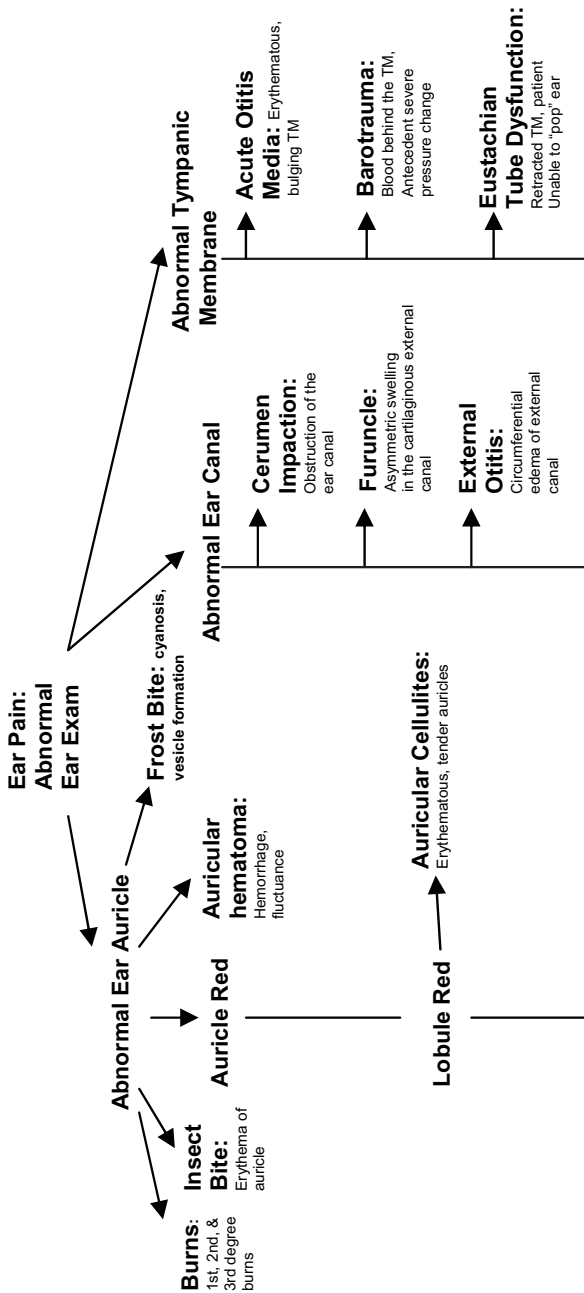
middle ear. Figure 2-2 shows a brief description of the most common causes of otalgia with an abnormal ear exam.

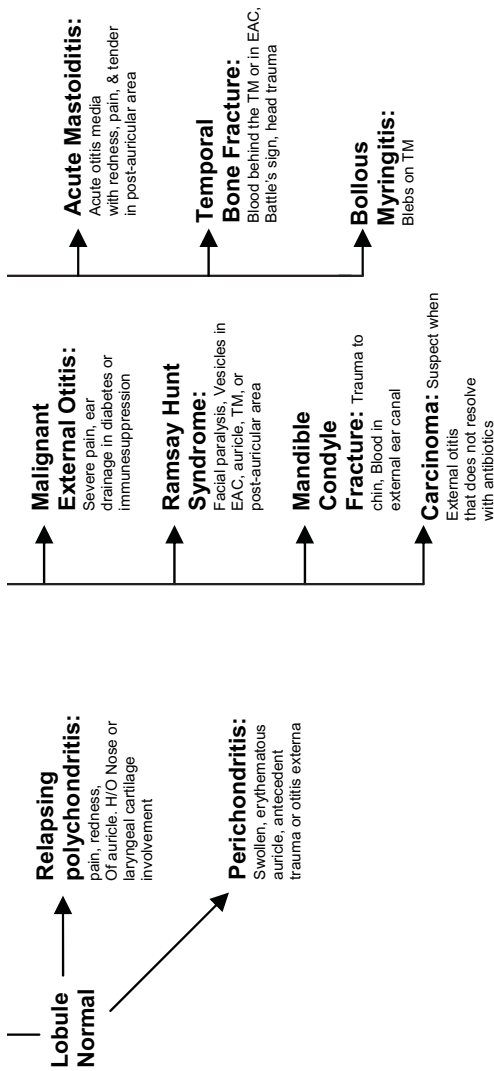
## RELAPSING POLYCHONDritis

Relapsing polychondritis (RP) is a rare, autoimmune condition that is characterized by recurrent inflammation and subsequent destruction of cartilage in the ear, nose, Eustachian tube, joints, trachea, and ribs. The underlying pathology in RP is the development of antibodies that become reactive with collagen type II in various tissues. The disease also causes involvement of noncartilaginous organs such as kidneys, eyes, and peripheral or central vessels. RP is usually seen between the third and fourth decade of life.

### Signs and Symptoms

The patient may present with inflammation of the ear and/or nasal cartilage and will mainly complain of redness, pain, and eventually deformity of these organs. When the ear cartilage is involved, the main complaint is ear pain. Trachea involvement manifests with throat pain, hoarseness, and breathing difficulty that may need mechanical ventilation. Hands, knees, ankles, wrists, and feet are the joints that are typically involved in a migratory fashion in the RP patients. Other tissues that may be involved are cranial nerves, cardiac vessels, ribs, and cardiac membrane. Systemic symptoms such as fever, anemia, and fatigue may occur. On examination, the auricular cartilage will be swollen, red, and tender to touch. The lobule will be characteristically normal.





**Fig 2-2.** The most common causes of otalgia with an abnormal ear exam.

## Diagnosis and What Tests to Order

Diagnosis of the disease is entirely clinical. Inflammation in two of three of auricular, nasal, or laryngotracheal cartilages or inflammation found in one of three of the auricular, nasal, or laryngotracheal cartilages plus two other signs of the following: inflammatory arthritis, ocular inflammation, vestibular dysfunction, and hearing loss. An accurate history of previous inflammations involving the auricular cartilages, nasal cartilage, or laryngeal cartilage will help in establishing the diagnosis.

## Treatment and When to Refer

Glucocorticoids are the main therapy of the disease. Prednisone 1 mg/kg/day up to 80 mg per day is the mainstay of initial therapy. Long-term maintenance with prednisone is commonly required and is generally best done under the care of a rheumatologist. A referral to a rheumatologist is needed for long-term management. If eustachian tube involvement (middle ear effusion or tympanic membrane retraction) or laryngeal/tracheal disease is suspected referral to an otolaryngologist is also warranted.

## AURICULAR CELLULITIS AND ERYSIPLAS

Auricular cellulitis is a cutaneous and subcutaneous infection of the auricle and external ear usually caused by group-A *Streptococcus* or *Staphylococcus aureus* that usually follows a minor trauma. Erysiplas is com-



monly caused by streptococcal infection of the auricle and has the same symptoms and signs as cellulitis.

## Signs and Symptoms

The patient will present with a few days history of pain in the ear. Inquiry should be made about recent trauma, insect bites, or even minor abrasions of the ear skin. The infection may be an extension of an otitis externa. The auricle is warm to touch, tender, erythematous, and cervical lymphadenopathy is occasionally present. The auricle and the lobule will be red and tender (unlike relapsing perichondritis where the lobule is normal on examination).

## Diagnosis and What Tests to Order

The diagnosis is entirely clinical. Any purulent discharge should be sent for culture and antibiotic sensitivity studies. If facial cellulitis is present, a CBC with differential should be obtained. It is helpful to outline the edge of the erythema with a marker on the skin to monitor progress.

## Treatment and When to Refer

Patients with cellulitis are best treated with penicillinase resistant penicillins which are effective against gram-positive cocci. Amoxicillin/clavulonate 875 mg po BID for 10 days (in children, amoxicillin/clavulonate 90 mg/kg/day of amoxicillin with 6.4 mg/kg/day of clavulonate) will generally cover most of the offending bacteria. Quinolones (e.g., levofloxacin 500 mg po QD  $\times$  10 days) can be used as an alternative in adults,

and clindamycin 20 mg/kg/day divided Q6–8H can be used in children. If the infection appears to involve the cartilage (exquisite tenderness and blistering/blebs on skin) or systemic symptoms (fever) is present, the patient should be admitted for intravenous (IV) antibiotics with coverage of *S. aureus* and *P. aeruginosa*. A blood culture should also be obtained.

Cellulitis localized to the auricle in an immune-competent patient can be treated with oral antibiotics. Immune-suppressed or diabetic patients or those with extension of the cellulitis beyond the auricle need admission for IV antibiotics. Consultation of an otolaryngologist is recommended if the patient is admitted for IV antibiotics.

## PERICHONDritis

Perichondritis occurs when the infection of the skin of the auricle involves the cartilage. This can occur secondary to an insect bite, cellulitis, otitis externa, infected ear piercings, trauma, or burn to the auricle.

### Symptoms and Signs

The auricle will be erythematous and exquisitely tender to touch. Occasionally blisters or blebs may be present on the auricle.

### Diagnosis and What Tests to Order

The diagnosis is based on the examination. A culture of the exudate from the skin and peripheral blood should be obtained.

## Treatment and When to Refer

The patient should be admitted for intravenous antibiotics with antipseudomonal and anti-*Staph aureus* coverage until culture results have been established. The need for admission is due to the tenuous blood supply of the auricular cartilage which can become compromised with the infection and lead to complete loss of the ear cartilage. This will result in a floppy ear due to the loss of structure in the auricle. An otolaryngology consultation on admission is recommended.

## BURN OF THE EAR

Direct thermal injury, contact injury, and electrical burns are some common types of burns to the ear. The damage in the skin's outer layer may lead to cartilage infection and subsequent perichondritis or chondritis with final deformity of the cartilage.

## Symptoms and Signs

The first degree burns manifest with minor pain and erythema whereas the second degree burns develop blistering. Third degree burns are mostly painless due to full thickness involvement and loss of neural endings. Third degree burns may appear black in color.

## Diagnosis and Tests to Order

History and local signs are adequate for diagnosis and no diagnostic measure is required. A basic metabolic panel, and if signs of infection are present, a CBC with differential may be beneficial in the inpatient setting.

## Treatment and When to Refer

No specific treatment is suggested in the case of first degree burns. In second and third degree burns, administration of topical antibiotics with analgesics in addition to avoiding pressure on the involved tissue is recommended. In second degree burns, draining the vesicles with a sterile needle will help prevent infection of the vesicular fluid. Skin grafts and reconstruction are used in third degree burns. Debridement of the cartilage is usually avoided. First degree burns and localized second degree burns can be managed in a primary care setting. Extensive second degree burns of the auricle and third degree burns are best managed at a burn center in conjunction with an otolaryngology consultation.

## AURICULAR HEMATOMA

Auricular hematomas usually occur because of perichondrial vessel rupture in direct trauma to the ear. In some cases, the blood that accumulates between the perichondrium and cartilage deprives nutrients to the cartilage causing an organized hematoma and the development of a “cauliflower ear.” Cartilage necrosis and atrophy may also occur as a result of an auricular hematoma and can lead to a floppy auricle.

## Diagnosis and What Tests to Order

The diagnosis will be clinical. The auricle will be red and ecchymotic with fluctuance.

## Symptoms and Signs

The patient will present with a history of trauma and a hematoma. The cartilage may become necrotic and deformity of the ear may develop.

## Treatment and When to Refer

An incision is made over the hematoma and the hematoma is completely evacuated. Cottonballs soaked in Betadine™ ointment should be placed into the crevices of the auricle (outside of the skin) to prevent reaccumulation of the hematoma. A head dressing with sponges on and behind the auricle should be used with a head wrap to keep pressure on the auricle. Alternatively, dental rolls may be placed in the concha and in the crease between the helix and the antihelix, as well as behind the ear, and sutured through and through the ear to keep pressure on the auricle. The dressing should be removed in 5 days. Ideally, the patient should be referred for evacuation of the hematoma; however, when immediate access to an otolaryngologist is not available, follow-up with an otolaryngologist is recommended in 2 to 3 days after hematoma evacuation. (See Chapter 7 on Trauma to the Ear for more details.)

## FROSTBITE

Frostbite occurs when there is ice formation in the extracellular fluid. When the tissue temperature falls below 0°C, sensory input from the local neural endings is reduced causing the patient not to sense the impending frostbite.

## Symptoms and Signs

The cold exposure causes cyanosis that progresses to ischemia and pallor and later vesicle formation in the case of extravasation of the fluid. On examination, the auricle is commonly edematous and occasionally has intact or ruptured bullae.

## Treatment and When to Refer

Treatment is by rapid warming of the ear at the temperature of 38 to 42°C in a warm water bath and ibuprofen 600 to 800 mg po as soon as possible. Draining the vesicles with a sterile needle will help prevent infection of the vesicular fluid. Application of the topical aloe vera is suggested. Anti-*Staph. aureus* antibiotics, namely, cephalexin 500 mg po TID (children, 10 mg/kg TID) for nonpenicillin allergics, or clindamycin 150 mg po QID (in children, 15 mg/kg/day divided Q6-8H) for 1 week is suggested for prophylaxis. No debridement is performed until the necrotic tissue has completely demarcated—this may take several weeks. The use of snow or a radiating heat source for rewarming is contraindicated. Hospital admission is required in cases of hypothermia or with frostbite involving the extremities.

## OTITIS EXTERNA

Infection of the external ear canal can happen in the acute or chronic forms. Swimming, humidity, maceration of the ear skin, seborrheic dermatitis, and local trauma (with the use of cotton-tipped applicators or other foreign bodies) are predisposing factors for the

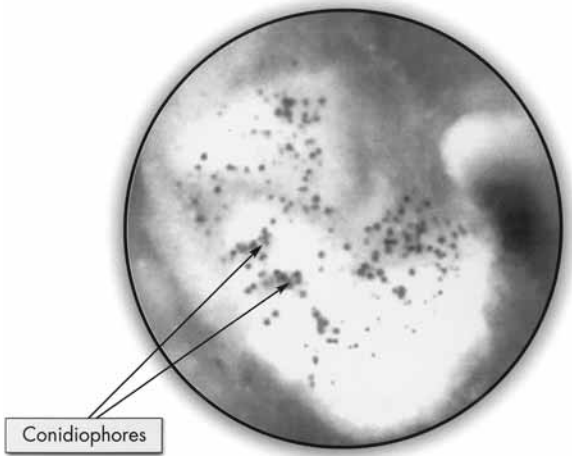
development of the external otitis. Acute or chronic otitis media can also secondarily cause otitis externa when the purulence drains into the ear canal and causes a local infection. The most common organisms are *Pseudomonas aeruginosa*, *Staphylococcus aureus*, *Staphylococcus epidermis*, and *Proteus vulgaris*. Fungal otitis externa may also occur and can be caused by a variety of organisms.

### **Symptoms and Signs**

The main complaint of patients in otitis externa is ear pain. Ear discharge, external auditory canal stenosis, and hearing loss might occur as the infection progresses. Itching occurs in the setting of fungal otitis externa or in chronic otitis externa, which is also generally fungal in origin. On examination, manipulation of the tragus usually causes pain. The external auditory canal is usually erythematous and inflamed and may seem narrower than the normal side. Drainage in the ear canal is commonly present, but if early in the disease process, it may not be present. The tympanic membrane is not involved initially but may become involved in a macerated pattern if the infection persists. Examination may not be possible at the end stage when an overwhelming pain is developed or the canal has narrowed greatly. Fungal otitis externa is distinguished from bacterial disease by the much thicker and yellow character of the drainage. Occasionally, black dots or white furry appearance of the fungus can be seen in the ear canal among the pus (Fig 2-3).

### **Diagnosis and What Tests to Order**

The diagnosis is based on the pain and edema of the ear canal and the tenderness on movement of the auricle



**Fig 2–3.** Fungal otitis externa. Yellow sludgy drainage and black dots are characteristic findings. From Touma BJ and Touma JB. (2006). *Atlas of Otoscopy*. Copyright 2006. Plural Publishing, San Diego, Calif. Reprinted with permission.

or tragus. A culture of the drainage is necessary only in patients with diabetes and those with an immune-compromised status or in patients who have failed two courses of ear drops.

### **Treatment and When to Refer**

Avoiding water and cleaning of the external auditory canal to remove the debris is critical for satisfactory treatment. Removal of the debris should be carried out with suction or cotton-tipped applicators, and water should not be used for cleaning. In the mild and



moderate external otitis, utilization of drops that contain anti-pseudomonal agents helps. Topical antibiotics that are commonly used are polymyxin, neomycin, and hydrocortisone (Cortisporin Otic Suspension or Solution<sup>®</sup>), ciprofloxacin with dexamethasone (Ciprodex<sup>®</sup>), and ofloxacin. All otic drops can be given as 3 gtt TID for 10 days, though ciprofloxacin with dexamethasone can be given as 4 gtt BID for 7 days. To be effective, antibiotics should have contact with the skin, which requires cleansing the canal of debris. In the severe external otitis, once the edematous external canal is to the point that it is closing or closed, or if obstructed by the excessive debris, a wick soaked in the antibiotic drops is placed in the ear canal for 5 to 7 days. Commercial ear wicks are available (eg, Otowick<sup>™</sup>) or one can be made by cutting a 2 mm × 2 mm × 2 cm sliver from a nasal tampon. The wick is lubricated with a small amount of antibiotic or other lubricant and placed entirely in the ear canal. The patient should be warned of the discomfort that the wick placement will cause temporarily. Oral antibiotics are rarely necessary and can be given in cases where the canal is closed or in cases of mild otitis externa in a reliable diabetic or immune-compromised patient (see malignant otitis externa for diabetic or immune-compromised patients). If oral antibiotics are used, ciprofloxacin 500 mg BID or levofloxacin 500 mg QD is given for 10 days.

Treatment of fungal otitis externa consists of debris removal using suction and irrigation of the ear with a solution of isopropyl alcohol and white vinegar. Isopropyl alcohol and white vinegar is mixed in a 50:50 mixture and the ear is irrigated three times a day using 10 cc of the solution in an ear (bulb) syringe for 10 days. The patient is asked to point the tip of the syringe superiorly in the lateral ear canal and with

gentle pressure to cleanse the ear canal. The patient should expect some mild dizziness that results from cooling of the ear canal that resembles caloric testing. The shoulder should be covered with a towel to gather the flushed debris and solution. Acetic acid drops can be given instead of irrigation as VoSol™ or VoSol HC™ (with hydrocortisone) 3 gtt TID for 10 days. The irrigation is preferred because it cleanses the ear canal of the significant debris that gathers as a result of fungal otitis externa. In cases of a tympanic membrane perforation, clotrimazole solution given with a dropper 3 gtt TID for 10 days works well.

Chronic otitis externa patients generally will have chronic itching of the ear and not as much pain. Treatment of chronic otitis externa consists of removal of debris from the external auditory canal and administration of VoSol HC™. Alternatively, nystatin and triamcinolone ointment (Mycolog™) can be given topically to be applied with a cotton-tipped applicator TID for 3 weeks. Hair care products (shampoo, conditioner, hair spray, etc) should be prevented from entering the ear by placing a cotton ball covered with an ointment or petroleum-based jelly (Vaseline™). The patient should be instructed to avoid itching the ears and warned not to use cotton-tipped applicators unless they are used for application of ointment. In resistant cases, topical calcineurin inhibitors (pimecrolimus or tacrolimus) ointments can be used TID for a 3-week period.

Patients with an external auditory canal mass, chronic otitis media, or if the infection is refractory to two different topical antibiotic drops should be referred to an otolaryngologist. Diabetic or immune-compromised patients who have severe pain or edema of the ear canal should be admitted to the hospital for IV antibiotic therapy and otolaryngology consultation.

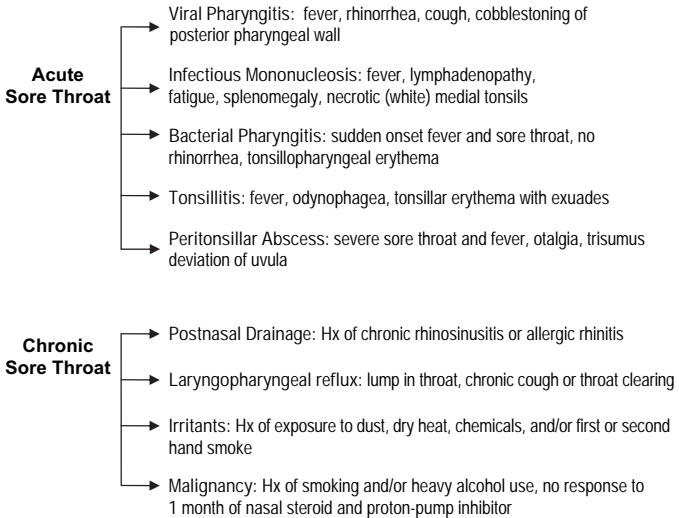
## CHAPTER 18

# *Sore Throat*

MEHDI SINA-KHADIV  
PAUL SCHALCH  
VICTOR PASSY  
HAMID R. DJALILIAN

### BACKGROUND

The pain and discomfort associated with a sore throat drive millions of children and adults to seek medical attention in emergency departments<sup>1</sup> and from their primary care physicians annually, accounting for up to 2% of such visits, yet most sore throats are self-limited. The most common causes of sore throats are viruses, including the ones responsible for the common cold or influenza (Fig 18–1). The most important bacterial cause of sore throat is group A beta-hemolytic *Streptococcus* (GAS), accounting for about 10 to 30% of cases—it is also the major treatable cause of sore throat. The most common microbial causes of sore throat are listed in Table 18–1. One of the major challenges physicians face when dealing with sore throat is identifying those patients who require specific antimicrobial agents



**Fig 18–1.** The most common causes of sore throat.

and attempting to minimize the unnecessary use of these agents in patients who will not benefit from such therapy. With rare exception, GAS is the only treatable cause of sore throat; however, 75% of patients seen by physicians receive antibiotic therapy. The discussion in this section focuses on acute versus chronic causes of sore throat as well as adult versus pediatric causes of sore throat.

**ADULT ACUTE SORE THROAT**

**Viral Pharyngitis**

Viruses are responsible for 85 to 95% of sore throats in adults.<sup>2</sup> The major causes of viral pharyngitis include influenza, parainfluenza, coronavirus, rhinovirus, adenovirus, enterovirus, herpes simplex virus (HSV), Epstein-

**Table 18–1.** Microbial Causes of Acute Pharyngitis

	<i>Pathogen</i>
<b>Bacterial</b>	Streptococcus, group A
	Streptococcus, groups C, G
	Mixed anaerobes
	<i>Neisseria gonorrhoeae</i>
	<i>Corynebacterium diphtheriae</i>
<b>Viral</b>	Rhinovirus
	Coronavirus
	Adenovirus
	Herpes simplex type 1 & 2
	Parainfluenza
	Coxsackie A
	Epstein-Barr virus
	Cytomegalovirus
	Human immunodeficiency virus
	Influenza A, B

Barr virus (EBV), and the human immunodeficiency virus (HIV). None of these organisms presents a unique clinical picture which complicates the ability of physicians to distinguish among the pathogens. The major goal of the physician is to identify patients with GAS pharyngitis in order to prescribe antibiotics to these patients and to avoid treating viral causes of sore throat with antibiotics. The discussion here concentrates on the common viruses that cause pharyngitis (coronavirus, rhinovirus, and adenovirus).

### ***Symptoms and Signs***

Symptoms and signs of viral pharyngitis include sore throat, discomfort or difficulty in swallowing, fever,

tender and enlarged lymph nodes in the neck, and joint pain or muscle aches. The patients will commonly have postnasal drainage or nasal congestion. The examination shows mild to moderate erythema of the pharynx with cobblestoning of the posterior pharyngeal wall. This cobblestoning represents hypertrophy of pharyngeal lymphoid tissue.

### ***Diagnosis and What Tests to Order***

Several formulae incorporating epidemiologic and clinical factors of sore throat have been devised which improve diagnostic accuracy primarily by identifying patients with a very low risk of GAS infection. Factors indicating low risk include the absence of fever and pharyngeal erythema, and the presence of obvious signs and symptoms of a viral upper respiratory infection (URI)—nasal congestion and drainage, cough. Unless the clinician can rule out streptococcal infection with great confidence on the basis of clinical and epidemiologic evidence, patients with acute pharyngitis should be tested for the presence of GAS. This can be done with either a throat culture or a Rapid Streptococcal Antigen Test (RSAT). A negative RSAT and the presence of signs and symptoms of a viral URI allow for the diagnosis of viral pharyngitis. Occasionally in the early stage of strep pharyngitis, the RSAT may not be positive but the culture examination will show GAS growth. Therefore, it is recommended that a culture of the pharynx be obtained when signs and symptoms of a URI are absent and RSAT is negative.

### ***Treatment and When to Refer***

Symptomatic patients will benefit from rest, maintenance of adequate oral hydration, acetaminophen and nonsteroidal anti-inflammatory drugs (NSAIDs) if fever

and pain are present, and gargling with warm salt water. Over-the-counter lozenges containing menthol and mild local anesthetics also provide temporary relief from severe throat pain. Topical lidocaine spray can be used for symptomatic relief as well. For a great majority of cases of viral pharyngitis, no further therapy is necessary; however, if patients encounter difficulty breathing, or have sore throat for greater than two weeks, they should be referred to an otolaryngologist for further workup.

## **Infectious Mononucleosis**

Infectious mononucleosis (IM) is an illness caused by the Epstein-Barr virus. EBV is transmitted by intimate contact with body secretions, primarily oropharyngeal secretions such as saliva. Coughing, kissing, and sharing utensils all contribute to EBV transmission.

### ***Symptoms and Signs***

The classic features of IM include the triad of fever, sore throat, and lymphadenopathy in the presence of fatigue. Occasionally, splenomegaly, palatal petechiae, and rash (following ampicillin or amoxicillin administration) are seen. The fever is usually low grade and chills are uncommon. A history of sore throat frequently is accompanied by pharyngeal inflammation and tonsillar exudates which can appear white, gray-green, or even necrotic (The classical appearance of the tonsils in IM is that of medial necrosis on both tonsils). Additionally, palatal petechiae with streaky hemorrhages and blotchy red macules can be present, although this finding has also been seen in patients with streptococcal pharyngitis. Characteristically, the lymphadenopathy is symmetric and more typically involves the anterior

and posterior cervical chains with large and moderately tender nodes. Also, a distinguishing feature of sore throat caused by IM is that the lymphadenopathy may become more generalized. Lastly, the lymphadenopathy peaks in the first week and then gradually subsides over 2 to 3 weeks. Recent studies have shown that in patients with IM, lymphadenopathy was present in all patients, fever in 98%, and pharyngitis in 85% of patients.<sup>3</sup> IM typically presents with a prodrome of malaise, headache, and low-grade fever before development of these more specific signs.

### ***Diagnosis and What Tests to Order***

In young adults with the classic triad of fever, sore throat, and lymphadenopathy, EBV-induced IM should be suspected. The necrotic appearance of the medial aspect of the tonsils is a characteristic finding. To confirm clinical suspicion, a test for heterophile antibodies (Mono spot test) and a peripheral blood smear can be ordered—patients positive for heterophile antibodies are diagnosed with IM. Furthermore, a peripheral blood smear with atypical lymphocytosis in heterophile-positive patients more sensitively diagnoses IM. Lastly, in patients with early signs and symptoms of IM, a negative heterophile antibody test should not rule out EBV infection, as the rates of false negative tests can reach up to 25% in the first week of infection. A repeat heterophile antibody test or tests for specific EBV antibodies should be performed.

### ***Treatment and When to Refer***

The standard approach to treating individuals with IM is supportive care. Acetaminophen (500 Q 6hrs) and NSAIDs reduce or entirely alleviate the fever, sore throat, and malaise that plague infected persons. Ade-



quate oral hydration and nutrition are also important. Finally, adequate rest is important; however, complete bed rest is both unnecessary and discouraged. Referral to an otolaryngologist is warranted if the clinical picture and laboratory are conflicted.

The use of corticosteroids in the treatment of EBV-induced IM has not been demonstrated to be effective. A meta-analysis of seven studies did not find sufficient evidence to recommend steroid treatment for symptom relief; moreover, two studies reported severe complications in patients receiving corticosteroid compared to placebo.<sup>4</sup> Therefore, corticosteroid therapy is not recommended for routine cases of IM as it is generally a self-limited illness. Patients with IM should be seen by a specialist if symptoms persist beyond 3 to 4 weeks or signs or symptoms of airway obstruction or splenic rupture become apparent. The patient should be advised against participating in activities that involve contact to the abdomen (eg, sports, etc) to prevent the possibility of a splenic rupture.

## **Bacterial Pharyngitis**

There are a number of bacterial organisms that can cause sore throat—including group A *Streptococcus*, non-group A *Streptococcus*, mixed anaerobes, and *Neisseria gonorrhoeae*. Of these organisms, GAS is the major treatable cause of sore throat.

### ***Group A Beta-Hemolytic Streptococcus***

GAS accounts for approximately 5 to 10% of cases of sore throat in adults.

**Symptoms and Signs.** The characteristic clinical findings suggestive of GAS pharyngitis include a sudden

onset of sore throat and fever, tonsillopharyngeal exudates, anterior cervical lymphadenitis, and leukocytosis. It is important to note that if cough and rhinorrhea are present, a viral cause of sore throat is more likely.

**Diagnosis and What Tests to Order.** It is of utmost importance for the physician to determine if a case of sore throat is caused by GAS versus other microbial causes; in such a case, the Centor criteria may be useful. The Centor criteria call for evaluation of patients with sore throat for, (1) tonsillar exudates, (2) tender cervical adenopathy, (3) fever, and (4) lack of cough. The more criteria that are met, the higher the likelihood of GAS infection and thus the need to perform either a RSAT or pharyngeal culture to confirm the diagnosis. The presence of three or four of the criteria indicates that the chance of GAS is approximately 40 to 60%. The absence of three or four of the criteria indicates a 20% chance of GAS infection.

**Treatment and When to Refer.** The treatment of choice for group A streptococcal pharyngitis is a 10-day course of oral penicillin (Pen VK 500 mg po QID, in children amoxicillin 90 mg/kg/d divided TID) because this agent has proven efficacy, a narrow spectrum, safety, and low cost. In cases of penicillin allergy, erythromycin (400 mg po QID, in children 40 mg/kg/d divided TID) or azithromycin (500 mg po QD for 3 days, in children 10 mg/kg/d divided QD for 3 days) can be used. When treating GAS pharyngitis, the objectives are to prevent supportive complications such as peritonsillar or retropharyngeal abscess, cervical lymphadenitis, and renal or cardiac valvular involvement. Treating GAS will prevent rheumatic fever and decrease infectivity. The patients generally will not spread the infection after 72 hours of antibiotic therapy and may return to work/school at that point. Typically, antibiotics do not shorten

the clinical course of the disease significantly as the great majority of patients with sore throat caused by GAS will have resolution of symptoms within 3 to 4 days even without therapy. The antibiotics will help reduce the chance of complications of GAS including rheumatic heart disease, and so forth. If there is no resolution of symptoms after treatment, or patients begin to complain for difficulty breathing or "hot potato" voice, or on examination there is medial displacement of the tonsils, lateral displacement of the uvula, or trismus, the patients should be referred to an otolaryngologist for evaluation of a peritonsillar abscess. Patients with more than 6 GAS infection in a year will benefit from tonsillectomy as the tonsils are colonized by GAS and cause the recurrent infection.

### ***Neisseria gonorrhoeae***

*Neisseria gonorrhoeae* is a rare, sexually transmitted cause of acute pharyngitis seen in some patients. Although colonization of the pharynx with *N. gonorrhoeae* is usually asymptomatic, clinically apparent pharyngitis sometimes develops, and pharyngeal colonization may be associated with disseminated disease.

**Symptoms and Signs.** When symptomatic oral infections occur, pharyngitis is the most common manifestation. Most commonly these patients will present after 10 days of penicillin therapy for a presumed strep pharyngitis with continued symptoms. Signs to look for on exam include an erythematous pharynx, bilateral tonsillar enlargement, significant exudates, and other signs of *N. gonorrhoeae* infection such as urethral discharge and dysuria.

**Diagnosis and What Tests to Order.** The diagnosis should be confirmed by throat culture on Thayer-Martin medium.

**Treatment and When to Refer.** If the case is uncomplicated, treatment consists of a single 125-mg dose of intramuscular ceftriaxone. Cefixime 400 mg orally in a single dose can be given. Consideration should be given to treatment of possible concomitant chlamydial urethritis infection as the two tend to occur together commonly. If the above treatment fails, the patient should be referred to an otolaryngologist.

## **Tonsillitis**

The tonsils are lymphoid tissues that act as part of the immune system to clear bacteria and other microorganisms from the oropharynx. When foreign matter enters the body through the mouth, the tonsils act as a filter—trapping microorganisms and setting off the immune response to attack the invading particles. The resulting immune reaction is a kind of low-grade infection in the tonsils. Tonsillitis occurs when the infection gets more serious, and the tonsils become painful and inflamed. Like other causes of sore throat, most cases of tonsillitis are viral and less often caused by bacteria.

### ***Symptoms and Signs***

The typical features of tonsillitis include red, inflamed tonsils, white or yellow tonsillar crypts or exudates, sore throat with painful swallowing, fever, and enlarged lymph nodes in the neck.

### ***Diagnosis and What Tests to Order***

The diagnosis of tonsillitis involves clinical suspicion, a thorough physical examination, and laboratory tests including throat culture or RSAT, a CBC to rule out a

more serious infection, or a heterophile antibody test to determine if the sore throat is caused by IM.

### ***Treatment and When to Refer***

If the rapid strep test is positive or the throat culture grows streptococcus, a 10-day course of oral penicillin (Pen VK 500 mg QID) should be prescribed. If the cause of tonsillitis is determined to be viral, supportive care with acetaminophen and NSAIDs for fever and pain, adequate oral hydration, gargling with salt water, and lozenges containing menthol and local anesthetics (eg, lidocaine spray) are enough to provide symptomatic relief until the tonsillitis resolves. Recurrent tonsillitis (more than 6 per year) warrants a referral to an otolaryngologist for a tonsillectomy. Other reasons for referral include asymmetric tonsils, tonsillar hypertrophy in a post-transplant patient, or infection spread beyond tonsils (eg, peritonsillar abscess).

### **Peritonsillar Abscess**

Peritonsillar abscesses are the most common deep infections of the head and neck in adults with the highest incidence between the ages of 20 to 40 years. Traditionally, peritonsillar abscesses have been regarded as the endpoint of a spectrum that begins as acute tonsillitis, progresses to cellulitis, and eventually forms an abscess in the capsule that attaches the tonsil to the pharyngeal wall. A group of 20 to 25 mucous salivary glands, called Weber's glands, located in the space just superior to the tonsil in the soft palate, have been implicated in the formation of peritonsillar abscesses.<sup>5</sup> Weber's glands function to clear the tonsillar area of any trapped debris and if they become inflamed, local cellulitis can develop—the resulting scarring and obstruction

of the ducts that drain these glands may progress to abscess formation. A peritonsillar abscess can progress into a parapharyngeal space abscess. A parapharyngeal space abscess will then progress inferiorly and compromise the airway at the hypopharyngeal level.

### ***Symptoms and Signs***

Patients with peritonsillar or parapharyngeal space abscess present with severe sore throat (that can be unilateral), fever, malaise, odynophagia, and otalgia. The throat pain is significantly worse on the affected side and is often referred to the ear on the same side (because of the irritation of the glossopharyngeal nerve that travels behind the tonsil). On physical examination trismus (inability to open the mouth) is a common finding and may complicate the examination. With a clear view of the oropharynx, there may be an obvious abscess at the superior pole of the affected tonsil and markedly tender cervical lymphadenitis may be palpated on the affected side. Alternatively, instead of seeing the exudate, the affected tonsil may be extremely swollen with contralateral deviation of the uvula. Swallowing is also highly painful, resulting in pooling of saliva or drooling. Patients often speak in a muffled or “hot potato voice.”

### ***Diagnosis and What Tests to Order***

Peritonsillar abscesses are almost always first encountered by primary care or emergency department physicians, and those with appropriate training and experience can diagnose and treat most patients. The diagnosis of peritonsillar abscess frequently is made based on a thorough history and physical examination. The differential diagnosis is lengthy and includes infectious mononucleosis, peritonsillar cellulitis, and

parapharyngeal abscess. In cases when the diagnosis of peritonsillar abscess is in question, radiographic imaging or the finding of pus on needle aspiration above the tonsils may help confirm the diagnosis. Ultrasonography, either transcutaneous or intraoral, can be helpful in identifying an abscess and in distinguishing peritonsillar abscess from peritonsillar cellulitis. If it is suspected that the infection has spread beyond the peritonsillar space or some complication involving the lateral neck space is suspected, a computed tomography (CT) scan with contrast is needed.

### ***Treatment and When to Refer***

The keys to effectively treating peritonsillar abscesses are to adequately drain the abscess and start antibiotic therapy—this combination results in resolution of the abscess in 90% of cases. The main procedures for the drainage of peritonsillar abscesses are needle aspiration, incision and drainage, and immediate tonsillectomy. In the absence of a previous history of recurrent pharyngitis, a needle aspiration or incision and drainage above the tonsil are preferred to tonsillectomy. Needle aspiration or incision should be made after topical and injected lidocaine, though lidocaine generally does not work well in an infected area. The patient should be given a Yankauer suction to hold in their mouth to help with clearing saliva and any pus. A 16-g needle attached to a 10-cc syringe should be inserted above the tonsil where the greatest bulge exists. The needle should never be inserted lateral to the tonsil to avoid the external carotid artery. If the bulging area above the tonsil is pulsatile, otolaryngology consultation should be obtained prior to insertion of a needle due to the rare possibility of aberrant carotid artery course.

Initial empiric antibiotic therapy should include antimicrobials effective against group A *Streptococcus*

and oral anaerobes. The favored regimens include oral amoxicillin-clavulanate (875 mg po BID  $\times$  10 days, children 40 mg/kg/d divided BID) or clindamycin (300 mg po QID for 10 days, children 20 mg/kg/d divided po QID  $\times$  10 days). The patient should be asked to eat some yogurt daily to prevent diarrhea. In emergency cases or if oral therapy cannot be used, parenteral ampicillin-sulbactam (1.5 g IV Q 6hrs, children 200 mg/kg divided Q 6hrs) or clindamycin (900 mg IV Q 8hrs, children 30 mg/kg/d divided Q 8hrs) can be used with equal success. Abscess pockets discovered on CT imaging that are less than 1 cm are generally treated with antibiotics and do not require drainage. The indications for admission include inability to drink with signs of dehydration and spread of infection beyond the peritonsillar area (see below). A parapharyngeal space abscess requires drainage through the neck and should be admitted to the hospital with an otolaryngology consultation for urgent management.

The complications of peritonsillar abscess are numerous and potentially fatal; they include airway obstruction, hemorrhage from erosion of the carotid sheath, thrombosis of the internal jugular vein, aspiration pneumonitis or lung abscess from ruptured peritonsillar abscess, mediastinitis, jugular vein suppurative thrombophlebitis—or Lemierre's syndrome. If any of these complications are suspected the patient should immediately be admitted to the hospital and otolaryngology consultation should be obtained.

## **Postnasal Drainage**

Postnasal drainage at the onset of a viral URI can cause a sore throat. For detailed information on treatment, see Chapter 13 on nasal discharge.