

Laryngeal Physiology for the Surgeon and Clinician

Second Edition

Clarence T. Sasaki, MD

The Charles W. Ohse Professor of Surgery
Director of the Yale Larynx Laboratory
Director of the Airway Consult Team
Yale School of Medicine
New Haven, CT



Contents

<i>Preface</i>	<i>vii</i>
<i>Introduction</i>	<i>ix</i>
<i>Foreword by Marvin P. Fried, MD, FACS</i>	<i>xi</i>
<i>Foreword by William Rosenblatt, MD</i>	<i>xi</i>
<i>Foreword by Reza Shaker, MD</i>	<i>xii</i>
1 Phylogeny and Function	1
2 Structure and Function	5
3 Innervation of the Larynx	13
4 Neurophysiology of Protective Function: Influence of Anesthesia and Level of Consciousness	19
5 Neurophysiology of Protective Function: Influence of Respiratory Phase and Proprioceptor Control	29
6 Neurophysiology of Protective Function: Influence of Hypoxia and Hypercapnia	35
7 Neurophysiology of Protective Function: Influence of Core Body Temperature	45
8 Evidence for a Laryngeal Motor Plexus	55
9 Neurophysiology of Respiratory Function	61
10 Phonatory Function	75
11 Neuromuscular Basis for Ventricular Phonation	81
12 Tracheotomy and Laryngeal Function	89
13 Laryngeal Paralysis	97
<i>Postscript</i>	<i>107</i>
<i>Glossary: Commonly Used Electrophysiological Terms</i>	<i>109</i>
<i>Index</i>	<i>111</i>

Preface

I am deeply indebted to Dr. John A. Kirchner, my professor, who not only encouraged my clinical devotion to the larynx but also turned his research laboratory over to me in 1975, when my bid to serve as principal investigator was initially supported by the National Institutes of Health. His chosen encouragement and his generosity were gifts I am fortunate to have received.

Without the tutelage of Dr. Masafumi Suzuki and Dr. Hiroyuki Fukuda, then Research Associates in Dr. Kirchner's laboratory, I would never have achieved the level of sustained interest or methodological skill necessary to mentor a succession of my own research fellows. Those dedicated students of the larynx since 1975 include Tadashi Akitaya, MD; Taketsugu Ikari, MD; Masatoshi Horiuchi, MD; Shigenori Haraguchi, MD; Shigeru Kano, MD; and Hiroyumi Matsuzaki, MD, all of Japan. Others include Young Ho Kim, MD, of Korea; Jagdeep Hundal, MD, of India; Zi

Wei Yu, MD, Jiajun Xu, MD, and Juan Li, MD, of P.R. China; Mikhail Wadie, MD, Basim Wahba MD, and Mina Sourial, MD, all of Egypt.

This textbook does not contain all the answers to challenges encountered in clinical practice, nor will its perusal endow the reader with the necessary capability to justify new operative procedures or derive new rehabilitative practices. While it does present a selective point of view, it does not intend to exclude competing perspectives generated by systematic inquiry. Rather, it is meant to serve as a guide for the serious trainee and as a reference manual for those discerning head and neck surgeons, speech-language pathologists, anesthesiologists and deglutologists who would seek to extend the boundaries of our knowledge in laryngeal physiology. If this book achieves these purposes, the effort of writing it will have been fully rewarded.

—CTS

Introduction

The larynx serves three important functions in man. In order of functional priority they are protective, respiratory, and phonatory. A sound understanding of these functional priorities appears essential to the management of the myriad diseases besetting this complex organ. This book explores these three categories of function in terms of phylogeny, functional morphology, and neuromuscular reflexes. Original experimental data from the Yale Larynx Laboratory, New Haven, Connecticut, will be included in order to support physiologic performance important to

our understanding of clinical behavior. In an effort to encourage clinical relevance, most chapters will be preceded by focused case presentations introducing relevant clinical descriptions. I am grateful to all of my residents, who have assisted in assembling the case presentations. These residents include Natalya Chernichenko, MD; Jen Chow, MD; Thomas Della Torre, MD; David Folk, MD; Jagdeep Hundal, MD; Jared Langerman, MD; Stella Lee, MD; Gregory Lesnik, MD; Adam LeVay, MD; Boris Paskhover, MD; Daniel Plosky, MD; and Julia Toman, MD.

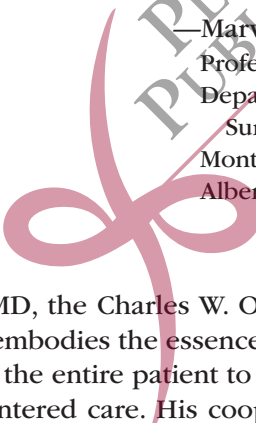


PLURAL
PUBLISHING
INC.

Forewords

The study and understanding of the human voice has gained increasing interest over the recent decades. Perhaps this is related to better methods of diagnosing laryngeal disorders or the more sophisticated techniques for treatment. The proliferation of laryngologists, well trained during fellowship, has helped to contribute to this process. Regardless, the fundamental understanding of the form and function of the fascinating laryngeal structure is basic to whatever will come next.

Clarence T. Sasaki is universally considered to be the preeminent laryngeal physiologist of our time. His insightful investigations, that have spanned 40 years of work, have made a monumental impact in our understanding of both normal and altered physiology, the basis of laryngology. This current textbook is a new and updated version of the first edition, already a classic in our field. It reflects Dr. Sasaki's personal and in-depth knowledge and experience that is second to none. This text will be invaluable for anyone involved in the study and care of patients with laryngeal disorders and will certainly be referred to repeatedly.



—Marvin P. Fried, MD, FACS
Professor and University Chairman
Department of Otorhinolaryngology-Head and Neck
Surgery
Montefiore Medical Center
Albert Einstein College of Medicine

Clarence T. Sasaki, MD, the Charles W. Ohse Professor of Surgery at Yale University School of Medicine embodies the essence of the clinician-teacher-scientist. He brings an understanding of the entire patient to the operating room and promotes an atmosphere of patient-centered care. His cooperation with our anesthesiologists has led to such innovations as preoperative endoscopy as practiced by head and neck cancer anesthesiologists worldwide.

The well-being of patients by all anesthesiologists is dependent on an appreciation of the function and reflexes of a delicate and vital organ, the larynx. This monograph, a synopsis of the work by Dr. Sasaki and others, gives the reader an in-depth understanding of the development, physiology, and function of the larynx. Such an exhaustive discussion of this topic cannot be found elsewhere and will serve as an important teaching reference for the anesthesiologist for years to come.


—William Rosenblatt, MD
Professor of Anesthesiology and Surgery
Yale School of Medicine
President and Founder of REMEDY
Past President of the Society for Airway Management

I am deeply honored to have been asked to write a foreword for the second edition of the highly popular book, *Laryngeal Physiology for the Surgeon and Clinician*. Professor Clarence T. Sasaki is to be commended for a truly superb achievement in advancing the field of laryngology.

Recent decades in medicine have witnessed the emergence of clinical fields with boundaries often extending beyond traditional disciplines and relying on multidisciplinary and transdisciplinary knowledge to optimize patient care and promote discovery and innovation. The need to better understand the physiology and pathophysiology of the larynx, uniquely exemplifies one of the important necessities for advancing several of these emerging transdisciplinary fields. This important evolution involving the larynx probably has some of its roots in the work of Chevalier Jackson and his contributions to laryngology, bronchology, and esophagology in the early part of the 20th century. Due to its anatomic location and physiologic interaction with the upper gut and the airway, knowledge of the three functional priorities of the larynx—protection, respiration, and phonation is pivotal for the advancement of deglutology and improvement of care for dysphagia patients as well as those with aerodigestive tract injuries induced by gastroesophageal reflux, some of the most common clinical disorders in need of progress in patient care. The transdisciplinary evolution is propelled to new heights by the comprehensive and in-depth contribution of Professor Sasaki in this important text. *Laryngeal Physiology for the Surgeon and Clinician, Second Edition* provides an invaluable source of knowledge to professionals in traditional disciplines in otolaryngology as well as those working in emerging transdisciplinary fields involving the upper gut, the aerodigestive, and the respiratory tracts.

—Reza Shaker, MD

Joseph E. Geenen Professor and Chief
Division of Gastroenterology and Hepatology
Director, Digestive Disease Center
Sr. Associate Dean and Director, Clinical and
Translational Science Institute of Southeast Wisconsin
Medical College of Wisconsin



John A. Kirchner, MD 2006



Masafumi Suzuki, MD 2000



Hiroyuki Fukuda, MD 2007

For Carolyn, Peter, John, Rachel, and Missy.



1

Phylogeny and Function

Laryngeal function may be best understood by an appreciation of its origin determined by primitive needs. In this regard Negus' masterful contributions are most illuminating¹ (Figure 1-1).

On an evolutionary scale, as animals migrated from an aquatic to a terrestrial

existence, a major change in respiratory requirements became necessary. According to Negus, these accomplishments were reflected in certain contemporary species of fish that developed unique respiratory modifications to allow intermittent sojourns on dry land. Notably, the climbing perch (*Anabas scandens*) possessed a respiratory diverticulum located above its gills (Figure 1-2A).

The Indian siluroid fish (*Saccobranchus*) also acquired a long diverticulum leading into an internal air reservoir. These structures, however, contained no valves to prevent the entrance of water when an aquatic existence was resumed.

The most primitive larynx may be found in the bichir lungfish (*Polypterus*), which inhabits the Nile River. The larynx of this fish consists simply of a muscular sphincter to guard against the entrance of water (Figure 1-2B). On the other hand, the African lungfish (*Protopterus*) and Australian lungfish (*Neoceratodus*) both possess, in addition to sphincteric musculature, discrete muscle fibers that effectively draw the valvular margins apart to produce active dilatation (Figure 1-2C). The muscular sphincter therefore remains contracted when the fish is in the water, but during periods of drought the sphincter is actively opened to allow air to be



Figure 1-1. Sir Victor Ewings Negus, 1887–1974. Courtesy of the National Portrait Gallery, London.

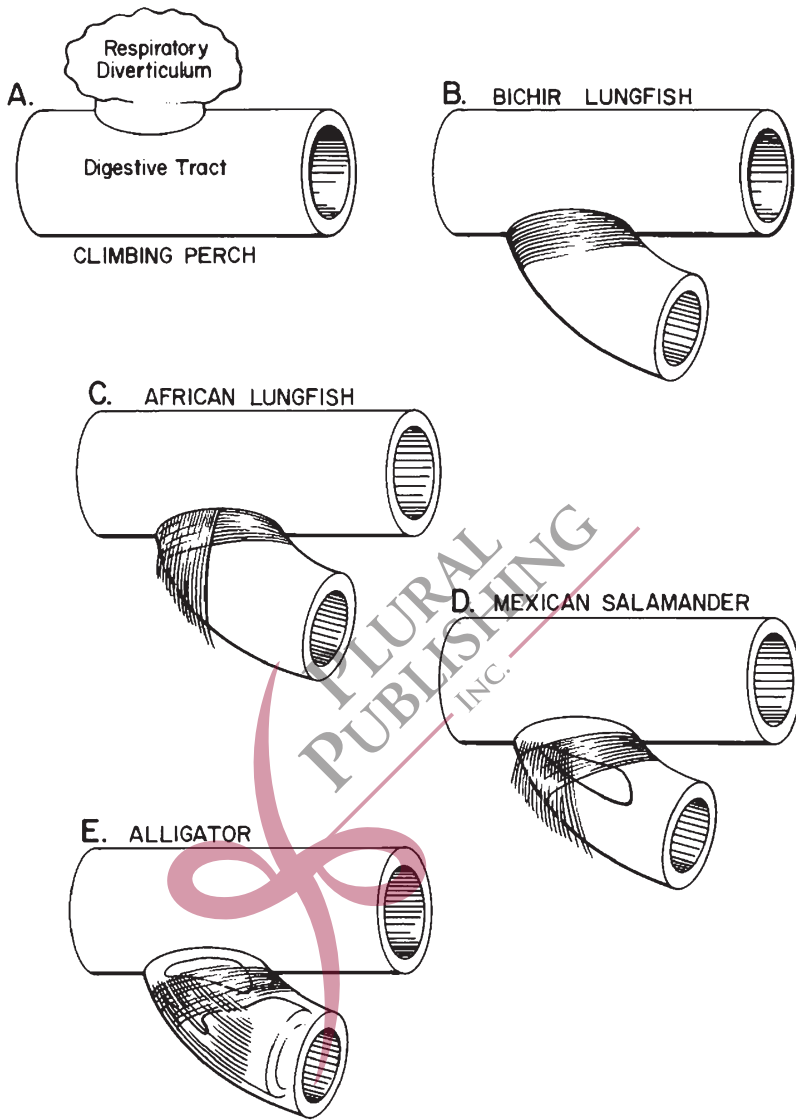


Figure 1–2. Structure and function of the larynx viewed phylogenetically (according to Negus). From English.² Figure 1. Copyright 1998 Lippincott Williams & Wilkins. Reprinted with permission.

gulped into the lungs by a swallowing maneuver. This capacity provides obvious advantages of respiratory survival when the supply of water is limited or undependable.

The primitive larynx, therefore, basically functioned as a simple sphincter to protect the lower airway from the intrusion of foreign matter. However, as respiratory requirements in a terrestrial

environment grew, the need for adequate ventilation also grew, accompanied by the necessary potential for active dilatation at the primitive sphincter.

To enhance ventilatory flow requirements through the laryngeal aperture, the acquisition of lateral cartilages may be noted in certain amphibians such as the Mexican salamander (*Amblystoma*). These lateral cartilages form bars on either side of the glottis to which the dilator muscles insert (Figure 1–2D). To augment the mechanical advantage of these muscles, a cartilaginous ring (giving origin to the dilator muscles) can be found between the glottis and trachea in other higher vertebrates. Such a configuration is apparent among reptiles such as the alligator (Figure 1–2E). Therefore, although the lateral cartilages of amphibians share a structural similarity to the arytenoid bodies of humans, the origin of the cartilaginous ring in reptiles can be compared to the cricoid cartilages in other mammals, including man.

Viewed phylogenetically through Negus' eyes, the primary function of the larynx is its use as a sphincter, protecting the lower airway from the intrusion of liquids and food. Its secondary function, supported by the sequential phylogenetic acquisition of the cricoarytenoid complex, centers on its role in respiration governed by active muscular dilatation of the laryn-

geal aperture. The third function of the larynx, phonation (best observed in mammals), appears to be a late phylogenetic acquisition.

Although the simple primitive larynx of *Polypterus* possesses the mechanism of airway constriction, thus exhibiting the potential for sound production, phonation using the larynx as a flutter valve is only seen in vertebrates possessing the respiratory requirements of an effective bellows. Such is possible only in the group of vertebrates possessing thoracoabdominal diaphragms, the group we call mammals. Nonetheless, among all mammals, man alone has acquired the potential for complex sound production using the laryngeal sphincter as a vibratory source. According to Negus, phonation is therefore considered the least significant of the three basic functions ascribed to this complex organ, whose primary role remains that of a guardian to the lower airway.

REFERENCES

1. Negus VE. *The Comparative Anatomy and Physiology of the Larynx*. London, UK: William Heinemann Medical Books; 1949.
2. English G. *Otolaryngology*. Philadelphia, PA: Lippincott Williams & Wilkins; 1998:chap 7, 2.

2

Structure and Function

The upper airway in adult man traverses the digestive tract in the region of the pharynx, complicating its sphincteric protection of the lower airway. By sharing a common passageway with the upper digestive system, the larynx is also compromised in its respiratory performance by resultant ventilatory turbulence and, therefore, resistance. Thus, the anatomical configuration in adult man that benefits phonatory purposes of the larynx simultaneously serves to compromise its sphincteric and respiratory functions. This functional dilemma is resolved at the laryngopharyngeal level by two important organic modifications: structural adaptation and delicate coordination among the three basic laryngeal functions as determined by precisely organized brainstem reflexes.

From a structural point of view, protective function of the adult human larynx is admittedly precarious by virtue of its low position in the neck (Figure 2-1B). Other mammalian species are provided with a relatively high-riding larynx, affording its close approximation with structures of the posterior nasal cavities. The intranarial position of the larynx, securing a continuous airway from the nose to the bronchi, therefore decreases the risk of pulmonary contamination by swallowed

matter. This structural modification is most obvious among certain cetaceans (Figure 2-2) and herbivores but appears to a lesser degree among carnivores that use an elongated epiglottis to effect nasolaryngeal connection during deglutition (Figure 2-3). In this regard, Negus considers the epiglottis to serve secondarily in an olfactory capacity, ensuring that inspired air enters exclusively through the nose. By a series of anatomic demonstrations in macrosmatic animals, this contention appears very convincing and is supported by later histologic work identifying epiglottic chemoreceptors similar in structure to taste buds of the oral cavity, implying epiglottic participation in chemosensory perception as well.³

It is of some interest that the human newborn exhibits similar nasolaryngeal connection by approximation of its epiglottis with the posterior surface of its palate, thus ensuring against aspiration by forming a continuous upper and lower airway (Figure 2-1A). The observation of obligate nasal breathing in the newborn period may be related to this anatomic configuration, which is lost between 4 and 6 months postnatally.⁴

In adult man the characteristic flat, shield-like configuration of the epiglottis serves to direct swallowed food laterally

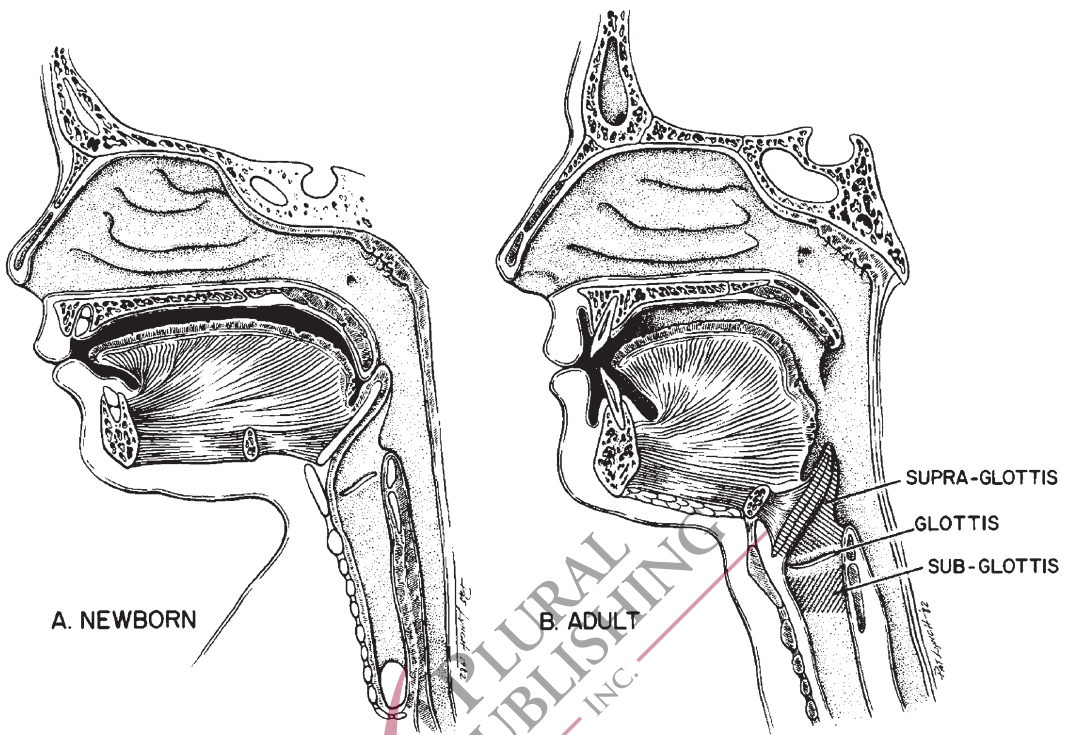


Figure 2-1. Nasolaryngeal relationship. From English.¹ Page 4. Figure 2. Copyright 1998 Lippincott Williams & Wilkins. Reprinted with permission.

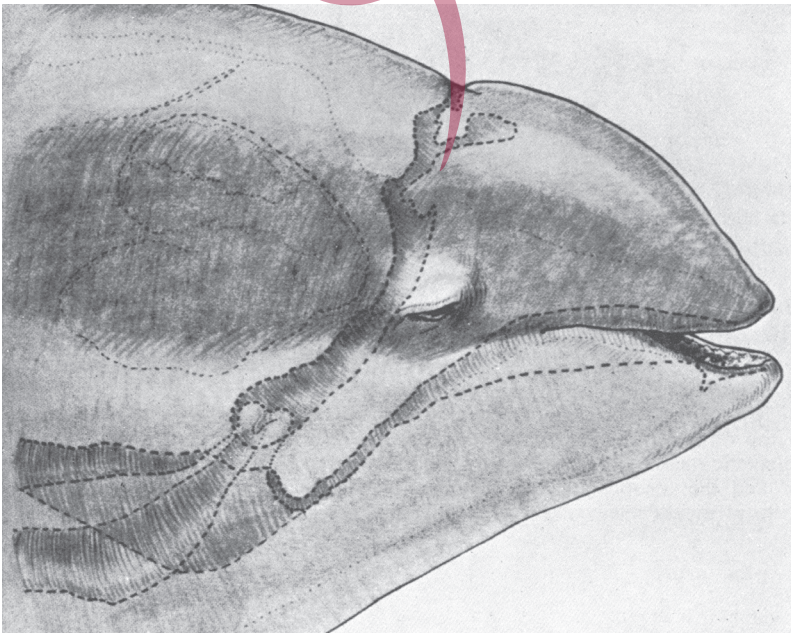


Figure 2-2. Head of a porpoise demonstrating the intranarial position of its larynx. From Negus.² Page 59. Figure 69. Copyright 1949 Heinemann Medical Books Ltd. Reprinted with permission.